

Management of herpes labialis triggered by emotional stress

Herlambang Prehananto¹ and Kus Harijanti²

¹ Department of Oral Medicine, Institut Ilmu Kesehatan Bhakti Wiyata, Kediri - Indonesia

² Department of Oral Medicine, Faculty of Dental Medicine, Universitas Airlangga, Surabaya - Indonesia

ABSTRACT

Background: Herpes labialis is a form of secondary or recurrence of primary herpes simplex infection. Herpes simplex virus is latent. It can reactivate due to reactivation of the virus induced by emotional stress, high fever, ultraviolet exposed, oral mucosal or nerve tissue trauma, immunosuppression condition, and hormonal disorders. **Purpose:** The study aimed to report the management of patients with herpes labialis on the lower lip triggered by emotional stress. **Case:** A 58 year-old woman complained of pain in her lower lip. The patient had suffered from the pain since one month ago. The patient had been treated with a lip ointment, triamcinolone acetonid 0.1% (Kenalog®), for 2 weeks, but became thick, dry, and worse. She said that she got many calamities related to her family, leading to the increased busyness and psychologically distressed conditions. Extra oral examination of the lower lip showed erythematous erosion sized 4x4 mm, yellowish red crusting sized 3x4 mm, and translucent multiple vesicles sized 1x1 mm with well circumscribed as well as irregular edges. On palpation submandibular lymph nodes, dextra and sinistra were palpable, rubbery, mobile and painless. Based on intra-oral examination, however, there were no abnormalities. **Case management:** The diagnosis was determined based on anamnesis, clinical examinations, and supporting examination of Ig M and anti HSV-1 Ig G. The patient then was prescribed systemic and topical Acyclovir. **Conclusion:** Some laboratory tests are necessary to confirm the diagnosis and determine the accurate therapy of herpes labialis in addition to the history and clinical features.

Keywords: herpes labialis; the lower lip

Correspondence: Kus Harijanti, Department of Oral Medicine, Faculty of Dental Medicine, Universitas Airlangg. Jl. Mayjend. Prof. Dr. Moestopo no. 47 Surabaya 60132, Indonesia. E-mail: kus_oralmedair@yahoo.com

INTRODUCTION

Herpes labialis is a form of secondary or recurrence of herpes simplex infection primary caused by type 1 herpes simplex virus (HSV).¹ HSV, categorized into the family Herpesviridae that has no animal vector, but spreads among individuals, is enveloped double-stranded DNA virus that has an ability to become latent in nerve cells of the host.² The first infection usually occurs after the first contact with HSV contained in fluid secretion of the mucosa, skin, and eye on infected patients. HSV can also move to sensory nerve axons, then settle and transform into chronic latent one in the trigeminal nerve ganglion. HSV can also move to outside the nerve cell and become latent, such as epithelium, primary leading to recurrences in lips.³

During the latent phase, HSV do not replicate, and HSV antigen will not be detected. HSV will be reactivated when

there are trigger factors, such as sun, trauma, emotional stress, or menstruation,⁴ fever, and immunosuppressing.⁵ HSV replicates in the ganglion, and then centrifugally move along the axon to the skin or oral mucosa. HSV infects epithelial cells, then clinically triggering vesicles that are easily broken into ulcers.⁴

Herpes labialis, occurs in 20-40% of the population in the United States, nearly 100 million times per year. The location of the occurrence is generally on lower lip, about one-third of the prevalence. Herpes labialis sufferers often complain of cold sores or fever blisters. They also complain of prodromal symptoms, such as tingling, itching or burning sensations followed by the appearance of lesions in the form of vesicles that are easily broken into ulcers accompanied with crusts. 60% of patients who experience prodromal symptoms tend to have larger lesions. Clinically, patients with herpes labialis will have vesicles on their lips, and

then in a matter of hours they will transform into ulcers and crusts. In the first 24 hours, patients with positive HSV culture then will have lesions, 80% of which are in the form of vesicles and 34% of which are in the form of ulcers or crusts. In more severe conditions, the healing process requires longer time.⁴ Generally, lesions are healed in 1-2 weeks without scars and bacterial secondary infection.¹

Furthermore, immunocompromised patients suffering from herpes labialis usually are given systemic Acyclovir therapy. Meanwhile, the use of topical antiviral medication aims to prevent replication, infectivity, pain, as well as wider size and longer duration of lesions. However, they cannot prevent the reoccurrence.¹ Topical antiviral medication, such as topical Acyclovir cream 5%, penciclovir cream 3%, and docosanol cream 10%, can effectively be applied three to six times a day on the lesions. Additionally, herpes labialis can be reduced by reducing the trigger factors, such as by using sunscreen cream.³ Therefore, case report was aimed to analyze the case of herpes labialis on the lower lip triggered by emotional stress

CASE

On January 25, 2014, a 58-year-old female patient came to the Dental and Oral Hospital, Universitas Airlangga, Surabaya with complaints of pain in her lower lip from one month ago. The patient had ever treated her wounds with a lip ointment of acetoniid triamcinolone 0.1% (Kenalog®) for 2 weeks, but her lip became thick, dry and getting worse. The patient consulted to a dentist, and was given a topical aloclair® gel that was used for 2 weeks. Unfortunately, her wounds were getting worse, and when the patient moved her lips, they were bleeding. One week before, the patient

felt unwell after consuming miloxicam once a day for 2 days. The patient had a history of cancer sores when under stress. She also had a history of allergy to tetracycline, and her child also has a history of allergy to seafood.

CASE MANAGEMENT

Extra-oral examination of her lower lip, showed reddish erosion sized 4 x 4 mm with irregular edges, crusts sized 3x4 mm with irregular edges, and transparent multiple vesicles sized 1 x 1 mm with clear edges (Figure 1A). On palpation of the submandibular lymph nodes, dextra and sinistra were palpable supple, mobile and painless. Intra-oral examination, showed no abnormalities.

Based on results of anamnesis and clinical examination, the patient then was diagnosed with herpes labialis, not pemphigus vulgaris. After that, the patient was referred to do a complete blood examination, such as SGOT, SGPT, fasting blood sugar (FBS), 2-hour postprandial blood sugar (PP or PG), BUN, creatinine, and total IgE, and then given Oxyfresh gel.

On the second visit the patient still felt pain. The topical medications also were used according to the instructions. The patient came to submit results of the laboratory tests. Results of the extra-oral examination showed that there were painful single erosion sized 5 x 3 cm with clear and irregular edges, reddish-yellow crusts, and vesicles on her lower lip. Results of the intra-oral examination did not reveal any abnormalities. Results of the complete blood laboratory test, moreover, showed that eosinophils was 1% (2-4%), lymphocytes was 38% (25-35%), erythrocyte sedimentation rate (ESR) was 26 mm (1-20 mm), and the number of eosinophils was 70 (80-360). Other laboratory

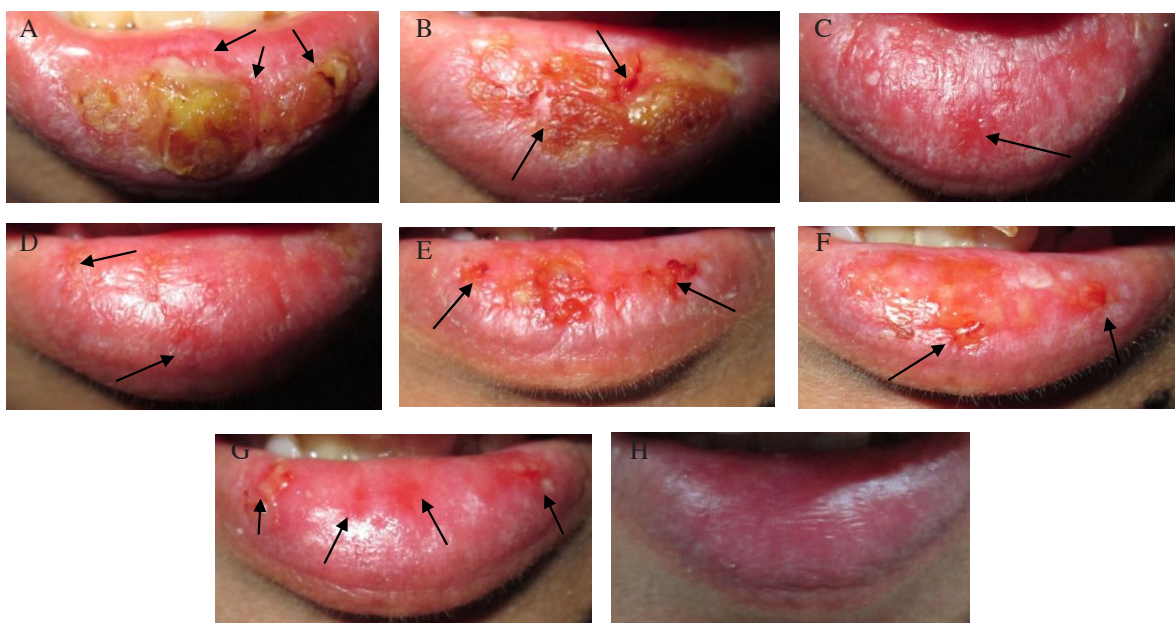


Figure 1. Extra-oral examination of the patient lower lip on: A) first; B) third; C) fifth; D) sixth; E) seventh; F) eighth; G) ninth; H) tenth visit.

results were still in normal limits.

On the third visit the patient felt that the wound on her lower lip was getting improved. The topical lip medications were also still used regularly according to the instructions. Results of the extra-oral examination showed red multiple erosions with clear and irregular edges, as well as crusts on her lower lip (Figure 1B). Results of the intra-oral examination showed no abnormalities. Therefore, the patient was instructed to perform serologic anti HSV-1 Ig M and Ig G tests, and came back to show the results of the lab tests.

On the fourth visit the pain on her lower lip was getting reduced, but sometimes the lower lip was still bleeding when used for eating and talking. The medications were still used regularly according to the instructions. She came to submit the results of the laboratory tests. Results of the extra-oral examination showed multiple erosions sized 3x4 mm with clear and irregular edges on her lower lip. Results of the intra-oral examination showed no abnormalities. In addition, the results of the laboratory results showed that anti HSV-1 Ig M was non-reactive, about 5.12 (non-reactive if index <9 ID U, reactive if index >11 EN U), while anti HSV-1 Ig G was reactive, about more than 50.08 (non-reactive if index <9 ID U, reactive if index >11 EN U). Consequently, the patient was instructed to reduce excessive activity and to consume foods high in calories and protein. Then, the patient was given the following prescription.

R/ Acyclovir 400 mg tab No. XXVIII
S 4 dd I
R/ Acyclovir cream tube No. I
S 3 dd I lit or
R/ immunomodulators (Imboost force®) capl no. X
S 1 dd I

On the fifth visit the patient felt that the wounds on her lower lip were getting improved (Figure 1C). The pain had also been reduced a lot. The medications were used regularly according to the instructions. Results of the extra-oral examination showed red multiple erosions with clear and irregular edges on her lower lip. The results also showed no crusts. And, results of the intra-oral examination did not reveal any abnormalities.

On the sixth visit the patient felt that the wounds on her lower lip were healed (Figure 1D). The pain had also been reduced a lot. The medication was used regularly according to the instructions. Results of the extra-oral examination still showed red multiple erosions with clear and irregular edges on her lower lip, and results of the intra-oral examination showed no abnormalities. Thus, the patient was instructed to discontinue the use of systemic Acyclovir, and then asked to use of Acyclovir cream and immunomodulators.

On the seventh visit the wounds appeared again on her lower lip. The patient said that a day before, she had outdoor activities without using any protection for her lip wounds. Consequently, her lower lip was exposed to volcanic

ash since at the time a natural volcanic disaster occurred (Figure 1D). Results of the extra-oral examination showed yellowish red multiple erosions sized 4 x 5 mm with clear and irregular edges on her lower lip. Results of the intra-oral examination did not reveal any abnormalities. Therefore, she was instructed to use a lip ointment, Acyclovir cream, as well as immunomodulatory regularly.

On the eighth visit the patient still felt the wounds on her lower lip. Her lower lip was even still bleeding when used for talking and eating. The medication was used regularly according to the instructions (Figure 1F). Results of the extra-oral examination showed yellowish red multiple erosions sized 3 x 4 mm with clear and irregular edges on her lower lip. Results of the intra-oral examination showed no abnormalities. As a result, she was instructed to stop applying the topical Acyclovir cream. The patient then was given the following prescription:

R / Hydrocortisone 0.125 gr
Kemisitn 0.125 gr
Lanolin 0.25 gr
Vaseline ad 1 g
m.f unguentum
S 4 dd I smeared on the lips

On the ninth visit the patient felt the wounds on her lips had been improved. Her lips were not dried and bleeding anymore (Figure 1G). The medication was used regularly according to the instructions. Results of the extra-oral examination showed that there were multiple red erosions, sized 3 x 2 mm with clear and irregular edges on her lower lip. However, results of the intra-oral examination showed no abnormalities.

On the tenth visits the patient felt the wounds on her lips had been improved. She even had no pain anymore (Figure H). The medication was used regularly according to the instructions. Results of the extra and intra oral examinations even did not reveal any abnormalities. Thus, the oral topical medication was stopped.

DISCUSSION

Herpes labialis is a recurrence or relapse of HSV-1 infection. One of factors triggering the recurrence of HSV is emotional stress. Patients suffering from herpes labialis will typically have prodromal symptoms of tingling, burning, or pain in a place where a lesion appears.¹

A 58-years-old patient came with a complaint of discomfort started one month ago. Prior to this complaint, she felt of dry and burn sensations on her lips, then vesicles appeared, and her lips became easily bleeding. Based on her anamnesis, this patient lately had many problem related to her family. Consequently, she was really busy, and her psychological condition was depressed. Three days before lesions appeared, the patient felt unwell. These might underlie a recurrence in this case.

Stress actually can reactivate latent herpes virus through an increase in one or more stress-related hormones (neuropeptides) directly inducing latent virus. Simultaneously, downregulation of cellular immune responses associated with stress can reduce an ability to control the cellular immune responses after reactivation of the latent virus. Psychological stress in humans increases levels of corticotropin-releasing factor (CRF) via the hypothalamus, then stimulating the pituitary gland to produce ACTH, which then stimulates the adrenal gland (HPA axis) to modulate immune interactions. Many researches on a relationship between neuroendocrine peptides and immune function modulation have focused on neuropeptide derived from the polyprotein pro-opiomelanocortin (POMC), especially ACTH and beta-endorphin. Nevertheless, as already mentioned, other hormones, such as cortisol, growth hormone, prolactin, catecholamines, epinephrine, and norepinephrine also have been reported to modulate body immune functions.⁶

On the first visit, results of the clinical examination showed a red erosion sized $\pm 4 \times 4$ mm with an irregular edge, reddish-yellow crusts sized 3×4 mm with irregular edges, and transparent multiple vesicles sized 1×1 mm with clear edges on her lower lip. In herpes labialis, in a matter of hours, a few fragile and short-lived vesicles will appear, break easily, and form shallow ulcers, then forming a coalition.¹

The differential diagnosis of these lesions was pemphigus vulgaris. Herpes labialis and pemphigus vulgaris have similar clinical symptoms on lips, such as easily broken vesicles, triggering red erosions or ulcers on the lips, stimulating yellowish crusts to appear after a few days. However, there are some differences between herpes labialis and pemphigus vulgaris. For instance, in pemphigus vulgaris, vesicles can be easily moved by a shearing force, called a positive Nikolsky sign. Meanwhile, in herpes labialis, vesicles cannot be moved easily by a shearing force. In addition, in herpes labialis, lesions can be found only on lips. Unlike in herpes labialis, lesions in pemphigus vulgaris can be found not only on lips, but also in oral mucosa.⁷

The diagnosis of herpes labialis sometimes can be confusing. To determine the diagnosis of herpes labialis, as a result, both further examination on complete blood and seroimmunological tests on anti HSV-1 Ig M and Ig G were conducted. Complete blood examination showed that lymphocytes increased to 38 (25-35%), most likely a viral infection. Erythrocyte sedimentation rate increased to 26 (1-20 mm) since the patient took Aspilets drug, and lesions on her lower lip was already getting chronic. Similarly, hematokrit increased to 0.50 (0.35 to 0.7) since the patient had a history of heart disease. Moreover, eosinophils decreased to 1 (2-4%) since she was under stress. Her -anti HSV-1 Ig G was reactive, more than 50.08 reactive (non-reactive if index <9 ID U, reactive if index >11 EN U). It means that the patient was positive with HSV-1. IgG is the most abundant immunoglobulin generated from gamma

globulin, accounting for about 75% of the total amount of immunoglobulin in the body. IgG provides protection against the virus. IgG is very important in the secondary response of the immune system.

When the immune system is faced with the antigen for the first time, the primary response is made by IgM followed by IgG level evaluation. IgG retains antigen memory, so the immune system will already have a memory against the antigen next time. Titers of anti-HSV IgG antibody will usually have increased by 1 to 2 weeks after the primary infection, reaching a peak at 6 to 8 weeks after the infection. Results of anti-HSV-1- IgM were non-reactive, about 5.12 (non-reactive if index <9 ID U, reactive if index >11 EN U). The increase in the titers of anti-HSV IgM antibody occurs a few days after the primary HSV infection⁸, and reached the peak after 2-4 weeks.⁹ IgM and IgG antibodies only give a picture of acute or chronic infections of simplex herpes disease.⁹

Another additional examination is smear on the ulcer to see the characteristics of the virus infection in the form of multinucleated giant cell. Nevertheless, this examination was not conducted since it could induce pain to the patient. In addition, results of the smear examination are still not specific to distinguish Varicella Zoster Virus infection or other viral infection. Direct fluorescent antibody (DFA) or immunoperoxidase antibody staining with smear preparation on vesicles actually will be more sensitive (70-88%), but the examination is difficult because it requires intake vesicular stadium frequently resulting in negative false.²

The patient was given a therapy using Acyclovir tablet 400 mg for 7 days with a dose of 1600 mg per day (4 x 1 tablet daily) and topical Acyclovir cream 50 mg three times daily. Acyclovir is an antiviral drug that is highly active against HSV-1 and HSV-2, as well as varicella zoster virus acting as inhibitors of the DNA polymerase and preventing viral DNA synthesis without affecting normal cellular processes. Acyclovir is also active against herpes virus, but cannot kill the virus.¹⁰ The secondary herpes can be controlled with systemic Acyclovir although reoccurrence cannot be prevented. Systemic Acyclovir prophylaxis is effective in cases of recurrent and stubborn problems and immunocompromised patients. The administration of topical Acyclovir is recommended for the treatment of secondary herpes. Acyclovir ointment 5% (or analog) is usually applied 5 times per day when the first symptoms appear in order to reduce the duration and severity of lesions.¹ Topical Acyclovir is a topical medication in cream, a semisolid dosage in the form of a thick emulsion containing water not less than 60% and one or more medication ingredients in order to increase soft and flexible senses of the lips, resulting in a decrease of the discomfort on the lips of patients.¹¹

Consequently, a supportive therapy is needed for patients with viral infections since they often experience a decrease in endurance. In connection with the weak condition of the patient, the administration of immunomodulators

(Imboost Force®) supplements is expected to improve the general condition of the patient. These supplements contain Echinacea, one type of herb. Some species of Echinacea plants are used to make a drug, extracted from leaves, flowers, and roots that pay a role as immunomodulators.⁸ Immunomodulator serves to enhance the immune system more active by increasing the body's immune system, both natural and adaptive.¹² As a result, this patient was instructed to have high protein/ high calorie diet, expected to increase the energy needed for the patient's healing process. Reducing her activities by taking a rest is also necessary to restore the patient's condition.

On the sixth visit, her clinical symptoms were getting improved. But, on the seventh visit, lesions appeared again on her lower lip. She said that she had done a lot of outdoor activities without protecting lesions on the lips (without using a mask). Therefore, the lesions were exposed to a lot of flying dust. In addition, the patient was also exposed to direct sunlight in a long time. In herpes labialis, lesions usually can heal without any scar within 1 to 2 weeks and secondary infection. Their exposure to direct sunlight constantly is suspected as an environmental trigger factor for the reoccurrence. Exposure to ultraviolet radiation (UV) from the sun as UV-B (wavelengths 280-320 nm) and UV-A (320-400 nm wavelength) can usually cause damage to the affected tissue. Exposure occurred continually then can cause loss of elasticity and tissue damage, especially exposure to UV-B.¹³ Thus, the lesions possibly appeared on the seventh visit.

Finally, the patient was given a lip ointment concoction of hydrocortisone, kemisetin, lanolin, and petroleum jelly. Hydrocortisone is a corticosteroid used as anti-allergen and anti-inflammatory. Corticosteroid can prevent allergic reactions, and reduce inflammation. Kemisetin is a broad spectrum anti-microbe that is effective against both gram-positive bacteria and gram-negative bacteria by inhibiting protein synthesis of microbial cells. Meanwhile, lanolin and petroleum jelly are the base materials for ointment, moisturizing stratum corneum, which can improve absorption and drug potential.¹⁰ On the tenth visit, after 10 days of the administration of the topical lip concoction (hydrocortisone, kemisetin, lanolin and petroleum jelly),

lesions on her lower lip were healed. It can be concluded that further investigations are necessary to confirm diagnosis of herpes labialis, and also determine proper treatment in addition to anamnesis and clinical description.

REFERENCES

1. Regezi JA, Sciubba JJ, Jordan RCK. Vesiculobullous diseases at oral pathology clinical pathologic correlations. United States of America: Elsevier Saunders; 2012. p. 1-6.
2. Costello M, Sabatini L, Yungbluth P. Herpes simplex virus infections and current methods for laboratory detection. *Clinical Microbiology Newsletter* 2006; 28(24): 185-92.
3. Woo SB, Greenberg M. Ulcerative, vesicular, and bullous lesions in burkets oral medicine diagnosis & treatment. 12th ed. Greenberg M, Glik M, Ship JA, editors. New Jersey: BC Decker Inc; 2015. p. 58-62.
4. Woo SB, Challacombe SJ. Management of recurrent oral herpes simplex infections. *Oral Surg Oral Med Oral Pathol Oral Radiol Endod* 2007;103(Suppl): S12.e1-18.
5. Lugito MDH, Pradono SA. Valacyclovir in the management of recurrent intraoral herpes infection. *Journal of Dentistry Indonesia* 2014; 21(1): 27-31.
6. Glaser R, Glaser JK. Stress-associated immune modulation and its implications for reactivation of latent herpesviruses. Columbus, Ohio: The Ohio State University Medical Center; p. 245-70.
7. Scully C. Oral and maxillofacial medicine the basic of diagnosis and treatment. London, United Kingdom: Curchill Livingstone Elsevier; 2013. p. 311.
8. Wilson DD. Manual of laboratory and diagnostic test. United State; America: The McGraw-Hill Companies; 2008. p. 619-20, 308, 341, 490, 564.
9. Mitaart AH. Infeksi herpes pada pasien imunokompeten. Surabaya: Prosiding Seminar Pendidikan Kedokteran Berkelanjutan New Perspective of Sexually Transmitted Infection Problems; 2010. p. 83-93.
10. Stoopler ET, Balasubramaniam R. Topical and systemic therapies for oral and perioral herpes simplex virus infections. *CDA Journal* 2013; 41: 259-62.
11. Lokesh P, Rooban T, Elizabeth J, Umadevi K, Ranganathan K. Allergic contact stomatitis; a case report and review of literature. *Indian Journal of Clinical Practice* 2012; 22(9): 458-62.
12. Djajakusuma TS. The role of immunomodulator in the treatment of sexually transmitted infection. Bandung: Medical Faculty of Padjadjaran University; 2010. p. 147-8.
13. Huber MA, Terezhalmay GT. Actinic cheilosis: etiology, epidemiology, clinical manifestations, diagnosis, and treatment. *Crest Oral-B Dental Care Continuing Education Course*, December 9, 2015; p. 2. Available at: <https://www.dentalcare.com/en-us/professional-education/ce-courses/ce400>.